

The Dellon Approach to Neurolysis in the Neuropathy Patient with Chronic Nerve Compression

Das Behandlungskonzept nach Dellon bei Patienten mit peripherer Neuropathie und chronischer Nervenkompression

Permission to print:

(Author's signature)

Autor

A. L. Dellon

Institut

Dellon Institutes for Peripheral Nerve Surgery, Johns Hopkins University, Baltimore, MD, USA

Key words

- below-knee reconstruction
- interdisciplinary plastic surgery
- foot
- nerve compression syndrome
- lower leg

Schlüsselwörter

- Unterschenkelrekonstruktion
- interdisziplinäre plastische Chirurgie
- Fuß
- Nervenkompressionssyndrom
- Unterschenkel

eingereicht 7. 11. 2008
akzeptiert 9. 11. 2008

Bibliografie

DOI 10.1055/s-2008-1039216
Handchir Mikrochir Plast Chir
2008; 40: 1–10 © Georg
Thieme Verlag KG Stuttgart ·
New York · ISSN 0722-1819

Korrespondenzadresse

A. Lee Dellon, M.D., Ph.D.
Professor of Plastic Surgery and
Neurosurgery
Suite 370
3333 North Calvert St.
Baltimore, MD 21218
USA
aldellon@dellon.com

Abstract

Impaired glucose tolerance creates a peripheral nervous system that is susceptible to chronic nerve compression. While it is accepted that surgical decompression of the median nerve at the wrist, for carpal tunnel syndrome, is appropriate in the diabetic, application of this concept to the lower extremity has not yet gained widespread recognition. Traditional electrodiagnostic studies demonstrate the presence of neuropathy, but usually are much less able to demonstrate superimposed nerve compression in the lower extremity in the presence of neuropathy. The clinician must rely upon the presence of a positive Hoffmann-Tinel sign to identify the patient with diabetic neuropathy and nerve compression. Combining sensory territories of common peroneal and tibial nerves gives a stocking pattern of sensory impairment. A positive Hoffmann-Tinel sign over the tibial nerve in the tarsal tunnel has a 90% positive predictive value for the diabetic patient to recover sensibility in the foot after decompression of the four medial ankle tunnels. A meta-analysis of clinical studies that have decompressed the tibial nerve branches at the ankle in diabetics with neuropathy and tibial nerve compression demonstrate pain relief in 80% of the patients from a mean of 8.5 on the VAS to 2.0, and demonstrate 80% of the patients recover more than just protective sensation. With sensibility partially restored, ulceration and subsequent amputation can be prevented. Balance can recover, and with it, morbidity from falls/fracture can be prevented. Hospitalization for foot infection can be reduced. This review includes description of the surgical approaches to accomplish these outcomes.

Zusammenfassung

Eine gestörte Glukosetoleranz im Stoffwechsel von Patienten bewirkt eine höhere Anfälligkeit peripherer Nerven für Kompressionssyndrome. An der oberen Extremität ist die Behandlung des Karpaltunnelsyndroms (KTS) durch operative Dekompression des N. medianus bei Patienten mit Diabetes mellitus als effektive Behandlungsmaßnahme anerkannt. Die Behandlung von Kompressionssyndromen an der unteren Extremität bei Patienten mit Diabetes mellitus hat dagegen bisher wenig Beachtung gefunden. Herkömmliche elektrophysiologische Untersuchungsverfahren können an der unteren Extremität zwar eine Neuropathie nachweisen, haben aber bei Vorliegen einer Neuropathie oftmals Schwierigkeiten, zusätzliche Nervenkompressionssyndrome nachzuweisen. Oft ist bei Patienten mit diabetischer Neuropathie und einem peripheren Nervenkompressionssyndrom ein positives Hoffmann-Tinel-Zeichen das einzige klinische nachweisbare Zeichen. Sind sowohl N. fibularis communis als auch N. tibialis von einem Nervenkompressionssyndrom betroffen, ergibt sich eine „strumpffartig“ angeordnete Sensibilitätsstörung. Ein positives Hoffmann-Tinel-Zeichen über dem N. tibialis im Tarsaltunnel hat nach Untersuchungen des Autors einen 90% positiven prädiktiven Wert für einen Patienten mit Diabetes mellitus, die Sensibilität wiederzugewinnen, wenn alle vier Engstellen am Sprunggelenk dekomprimiert werden. Metaanalysen von klinischen Studien weisen bei Patienten mit Diabetes mellitus, bei welchen eine operative Dekompression des N. tibialis und seiner Äste durchgeführt wurde, in 80% eine Schmerzreduktion von einem Punktwert von 8,5 auf 2,0 auf der visuellen Analogskala nach. Dabei erreichen 80% dieser Patienten mehr als nur Schutzsensibilität. Durch die teilweise wiederhergestellte Sensibilität im Fuß kann eine spätere Ulzeration oder gar Amputation oft ver-

Introduction

The neuropathy epidemic is now upon us [29,40,42]. Conservatively, 50% [25] of the 30 million diabetic people in the United States have neuropathy. There may be the same number of people with neuropathy of unknown cause [24,33]. Current chemotherapy strategies using taxol and platin derivatives [27,52], and now thalidimide for multiple myeloma [8], add cancer survivors to this list of patients with neuropathy. In general, with the exception of glycemic control for those with diabetes, there is no neuropathy cure or prevention available: neuropathy treatment is directed at amelioration of the pain symptoms [3,26,45]. It is predictable that this epidemic will create a greater number of wounds to heal, of lower extremities to amputate, and of falls associated with loss of balance. Morbidity related to upper extremity, hip and foot fractures, especially in the elderly with neuropathy, is well-known [30,48]. The burden to the health-care system and society is enormous, with that cost in 2002 having been estimated to be \$132 billion dollars [2].

There have been excellent reviews of the pathophysiology of impaired glucose tolerance and the susceptibility of the peripheral nerve to chronic nerve compression in the literature of specialties related to wound healing [15], pain management [16], orthopedic foot and ankle surgery [7] reconstructive microsurgery [50], and podiatry [17].

A Medical Controversy

It is now observed, reported, and agreed that among patients with neuropathy, a systemic problem, there are many who also have localized nerve compression, with that percentage estimated to be 33%, including sites in the upper and lower extremities [8,57]. Since the early 1980s, it has been my approach that these compressed nerves can be treated surgically, with relief of symptoms, but, clearly, without changing the underlying metabolic neuropathy [12]. Clearly, appropriately trained surgeons have the techniques available to them to decompress these localized compressions. It is the purpose of this review to present the historical development, and my current approach, to diagnosis and surgical treatment of chronic nerve compression in the patient with neuropathy.

For the surgeons reading this review, it is important to clarify that while my involvement in this subject spans the last quarter century, the main message remains confused or at least misrepresented by the Medical Community; in particular, a small group of diabetologists and neurologists [10,11]. They continue to miss the point that this review attempts to make perfectly clear: every patient with neuropathy should not have a peripheral nerve decompression. Peripheral nerve decompression is reserved for the patient with neuropathy who has a demonstrable compression of a peripheral nerve in a known site of anatomic narrowing.

mieden werden. Zusätzlich wird durch die verbesserte Sensibilität im Fuß auch das Gleichgewicht beim Gehen verbessert, sodass zusätzliche Folgeschäden durch Stürze wie etwa Frakturen ebenfalls reduziert werden. Die vorliegende Arbeit gibt eine Übersicht über das Behandlungskonzept und die chirurgische Vorgangsweise des Autors, um diese Ziele zu erreichen.

It remains appropriate to debate how to make the diagnosis of that nerve entrapment in the presence of neuropathy, as making the diagnosis of a nerve entrapment is still debated even in the upper extremity for carpal tunnel [46,54] and cubital tunnel syndrome [28] in the non-neuropathic patient, where electrodiagnostic studies have a false negative finding in 33% of symptomatic people [1]. The comprehensive study by Brill and co-workers continues to be the best arbiter of this problem [41]; they found that electrodiagnostic studies could not distinguish reliably the presence of carpal tunnel syndrome in the patient with diabetic neuropathy, and they concluded that the physician should rely upon the physical examination in making the diagnosis. My experience has demonstrated that the presence of a positive Hoffmann-Tinel sign over the tibial nerve in the tarsal tunnel gives a 92% positive predictive value for good to excellent results after nerve decompression in the diabetic with neuropathy and 88% in the patient with idiopathic neuropathy [34]. Therefore, the physical examination, and primarily the presence of a positive Hoffmann-Tinel sign, rather than confirmatory electrodiagnostic results, will remain the critical indication for the surgeon that a chronic nerve compression exists in the patient with neuropathy.

Surgical Indications/Contraindications

The ideal neuropathy patient to chose for decompression of peripheral nerves is one who has:

1. Symptoms, sensory and/or motor, in the distribution of the peripheral nerve.
2. Physical findings of a compressed peripheral nerve at the known sites of anatomic narrowing, which are, in the lower extremity:
 - a) common peroneal nerve at the fibular neck,
 - b) superficial peroneal nerve in the distal third of the leg,
 - c) deep peroneal nerve over the dorsum of the foot,
 - d) tibial nerve proximally at the soleus arch,
 - e) tibial nerve in the tarsal tunnels:
 - the tarsal tunnel itself,
 - the medial plantar tunnel,
 - the lateral plantar tunnel,
 - the calcaneal tunnel(s).
3. Documentation of neuropathy by either electrodiagnostic or neurosensory testing.
4. Failed to have symptoms improved by:
 - a) treatment of the underlying medical condition,
 - b) treatment-associated pain with neuropathic medications, non-steroidal anti-inflammatory medications, opioids.
5. Has sufficient circulation to heal lower extremity incisions:
 - a) presence of a palpable pulse,
 - b) skin turgor, color, and hair growth on the foot is normal,
 - c) does not have an infected wound on the foot,
 - d) in the absence of a pulse, has an ankle brachial index > 0.75
6. Has minimal or controlled pedal edema.

Table 1 Dellon triple nerve decompression in diabetics.

Study	Number of nerves	Pre-operative		Results: improved		New or recurrent ulceration/amputation
		Ulcers	Amputation	Pain	Touch	
Dellon, 1992 [14]	31	0	0	85%	72%	0%
Wiemann, 1995 [58]	33	13	0	92%	72%	7%
Chaffe, 2000 [9]	58	11	6	86%	50%	0%
Aszmann, 2000 [4]	16	0	0	n. a.	69%	0%
Tambwekr, 2001 [55]	10	6	4	n. a.	80%	0%
Wood, 2003 [60]	33	0	0	90%	67%	0%
Biddinger, 2004 [7]	22	0	0	86%	80%	0%
Lee, 2004 [34]	46	0	0	92%	92%	n. a.
Aszmann, 2004 [5]	50	0	0	n. a.	n. a.	0%
Valdivia, 2005 [56]	60	0	0	87%	85%	0%
Rader, 2005 [44]	49	0	0	90%	75%	0%
Yao, 2005 [61]	90	0	0	94%	90%	0%
DiNucci, 2005 [21]	72	0	0	80%	80%	0%
Steck, 2005 [53]	25	0	0	84%	72%	0%
Siemionow, 2006 [50]	36	0	0	90%	90%	0%
Yuksel, 2006 [62]	22	0	0	89%	85%	0%
Shaffiroff, 2006 [49]	300	0	0	85%	80%	0%
Nelson, 2007 [39]	9	0	0	88%	88%	0%
Massa, 2007 [37]	20	0	0	80%	86%	0%
Maloney, 2007 [36]	95	0	0	86%	83%	0%
Bae, 2007 [6]	33	0	0	75%	72%	0%
Perierra, 2007 [46]	120	0	0	80%	75%	0%

7. Has no medical contra-indications to a general or spinal anesthetic.

8. Is compliant with instructions and responsible for their own care.

A *poor candidate* for decompression of peripheral nerves in the lower extremity is someone who has/is:

- weighs more than 140 kilograms,
- has venous stasis or venous hypertension,
- has failed to improve from upper extremity nerve decompression,
- has “failed back” surgery,
- has insufficient circulation to heal after surgery.

Pre-Op Planning

The main “planning” to be done ahead of surgery is to be sure the patient understands:

- the concept of why they are susceptible to chronic nerve compression,
- the concept that they will still have their metabolic neuropathy,
- the regional anatomy of where the nerve is going to be released,
- that their numbness may be replaced by pain as the nerve regenerates,
- that some sensory improvement may occur immediately,
- that nerve regeneration will continue for at least one year,
- that they must walk to mobilize the nerve after surgery,
- that if they walk too much they may tear open their sutures,
- share the good news about this surgery:
 - sensation is restored in 80% of people (see [Table 1](#)),
 - pain is relieved in 80% of people (see [Table 1](#)),
 - new ulcerations are prevented (see [Table 1](#)),
 - in the presence of sensation, and in the absence of ulceration, amputation will be prevented too [5],
 - in the presence of sensation, balance is restored: falls and their fractures will be reduced [23].

Detailed Surgical Technique

General considerations

The surgeon must have spent time learning how to do this procedure, preferably in a workshop in which cadaver dissection has been provided and an experienced surgical teacher has demonstrated the procedures both in a cadaver and in a living patient. If this type of instruction is not available within the residency training program, then a formal workshop environment should be sought for this post-graduate education. Microsurgical experience is required to do an intraneural dissection. The surgeon must have a thorough understanding of the regional anatomy and the variations of the anatomy of the nerves to be decompressed.

The surgery is done as an outpatient procedure and can be done in a surgery center under general anesthesia. An antibiotic is administered *i. v.* by the anesthesiologist prior to inflating the tourniquet. A tourniquet is used, and set to 300 mmHg pressure. A bipolar coagulator is used. Loupe magnification is used. Appropriately delicate instruments and technique are required.

Common peroneal nerve at the fibular neck (CPN) [18, 38]

A 3- to 4-cm incision is made obliquely across the fibular neck, and deepened into the subcutaneous tissue. Care is taken not to injure the lateral cutaneous nerve of the calf, which is sometimes present. The deep fascia is palpated to identify the common peroneal nerve. This fascia is lifted and then incised to identify the CPN. This nerve often has a yellowish color and appears like a lipoma. Only the epineurium should be grasped in the forceps. The fascia is released into the popliteal fossa. Unless there has been trauma, this fascia is not attached to the CPN. The entrapment site is distal, beneath the peroneus longus muscle. The fascia of this muscle is divided transversely and longitudinally, the muscle retracted anteriorly. Beneath the muscle there is often a fascial band that must be released ([Fig. 1](#)). The CPN will

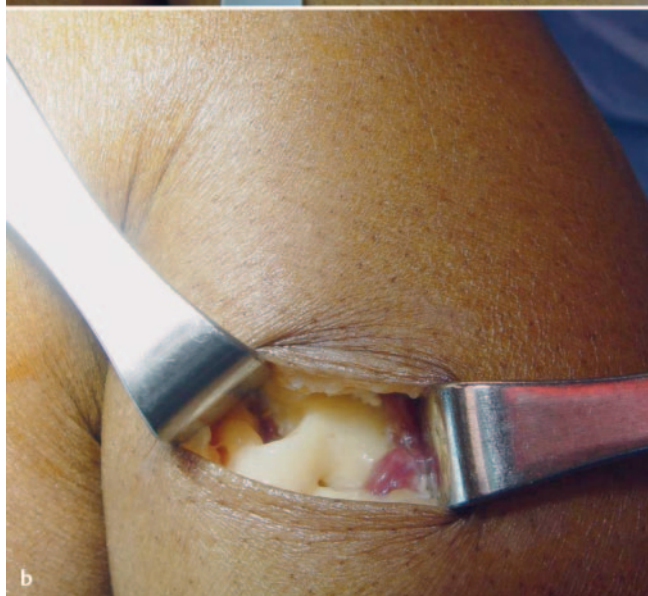
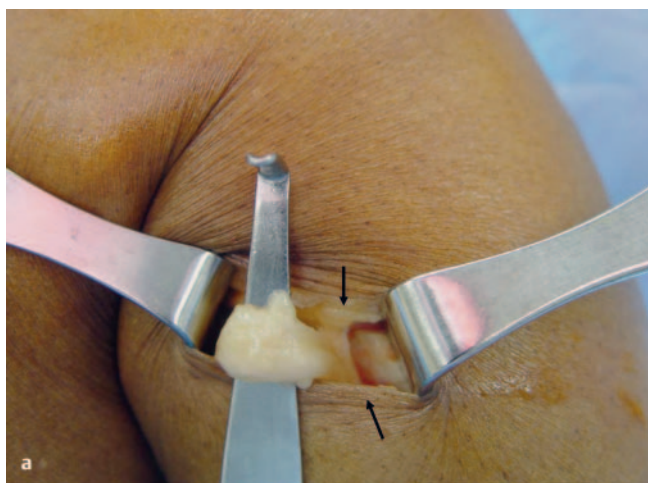


Fig. 1 a and b Neurolysis of the common peroneal nerve at the fibular neck. **a** The common peroneal nerve of the left leg is noted at the knee after opening the deep fascia. Note the nerve is compressed below the peroneus longus muscle by a white fibrous band. The peroneus muscle is retracted. **b** The white band has been excised. Note the indentation in the common peroneal nerve.

be indented beneath this band, and appear flattened. If the nerve is firm, an intraneural dissection may be done. The CPN must be elevated and any fascial bands on the lateral head of the gastrocnemius muscle beneath the CPN must be cauterized and then divided. The opening into the anterior compartment may be too narrow, in which case the soleus origin must be cauterized and then divided at the fibular in order to enlarge this entrance. This completes the dissection. A local anesthetic is put into the skin edges, avoiding getting any on the CPN. The dermis is sutured with interrupted absorbable suture, 4-0 monocril is preferred, and the skin is sutured with continuous 5-0 nylon, with one additional interrupted 5-0 nylon placed in the center.

Superficial peroneal nerve in the leg (ASPN) [47]

The SPN is depicted as being in the lateral compartment. However, at least 25% of the time it is also in the anterior compartment, and sometimes it is in both compartments. The SPN exits the fascia of the lateral compartment, on average, about 10 to

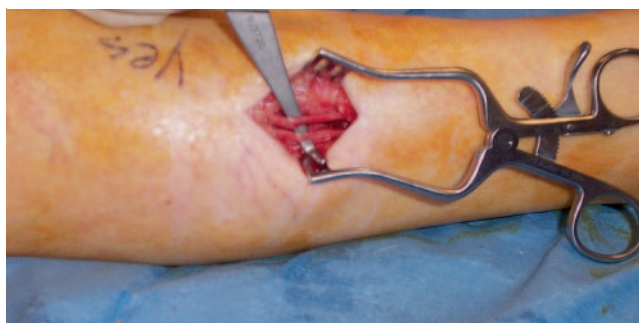

Fig. 2 Neurolysis of the superficial peroneal nerve. A variation is demonstrated in which there is a branch of the superficial peroneal nerve in BOTH the anterior and the lateral compartment. A fasciotomy of each compartment has been done and a neurolysis of each of the two branches has been completed.

12 cm proximal to the lateral malleolus. The incision for neurolysis of the SPN is typically parallel to the fibular, but anterior to the fibular to permit access to both anterior and lateral compartments. The incision may be more proximal or more distal depending upon the patient's height and the location of the positive Hoffmann-Tinel sign. The incision is made into the subcutaneous plane. Sometimes the SPN may already be in this plane, so be careful not to injure it. A small elevation from the fascia accompanied by a small blood vessel and some fat often mark the spot of the entrapment as the SPN travels from deep to the fascia to enter the subcutaneous plane. The fascia must be incised for about 15 cm so that the SPN is totally free from constriction and a new small muscle herniation is not created through a small fascial window.

Evaluate both the anterior and the lateral compartment even if a SPN is found in the first compartment you enter. If there is no SPN in either compartment, then it will lie within the septum itself [37]. Open the septum very carefully to be sure you do not injure an SPN branch located within the septum (● Fig. 2).

Cauterize the incised fascial edges, as the fascia is well-vascularized and can cause either a post-operative hematoma or a seroma. Close the skin with interrupted intradermal 4-0 monocril and continuous and interrupted 5-0 nylon.

Deep peroneal nerve over the dorsum of the foot (DPN) [13]

The deep peroneal nerve has been described as becoming entrapped in the anterior tarsal tunnel, which is a wide and deep space beneath the extensor retinaculum. In the absence of trauma to this region, this is not the site of compression in the patient with neuropathy.

- ▶ The deep peroneal nerve becomes entrapped in the patient with neuropathy beneath the extensor hallucis brevis tendon and the underlying bones, at the juncture of the 1st and 2nd metatarsals and the cuneiform. This is the site at which the Hoffmann-Tinel will give a distal radiation.
- ▶ The incision is made obliquely across this region. In the subcutaneous tissue, blunt dissection must identify the superficial peroneal branches so they can be retracted and not injured. The extensor hallucis brevis tendon is identified unambiguously, and then a 2-cm section of it is resected. An exploration is then done to identify the DPN medial or lateral to the dorsalis pedis artery (● Fig. 3).

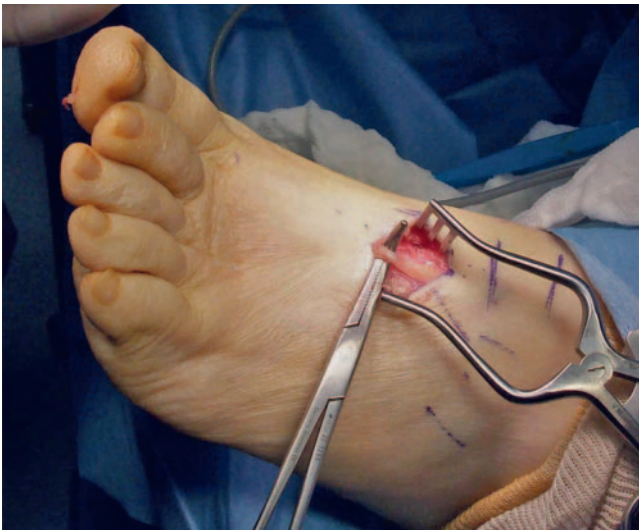

Fig. 3 Neurolysis of the deep peroneal nerve over the dorsum of the foot. Note that the extensor hallucis brevis tendon has been excised, and there is an indentation with proximal swelling of the deep peroneal nerve.

- ▶ Remember that about 5% of people do not have a dorsalis pedis artery. Remember that in some people there is no DPN, and those fibers are all carried by the SPN.
- ▶ Even in the absence of trauma, the DPN may be adherent to the underlying bone requiring a gentle neurolysis of the very small nerve. Typically, the nerve is swollen proximally, and is released until the inferior extensor retinaculum is reached.
- ▶ The skin is often too thin to place an intradermal suture, in which case the skin is closed with interrupted and continuous 5–0 nylon sutures.

Tibial nerve and its branches at medial ankle [14, 35]

First it is important to appreciate that there are four tunnels to decompress: 1) the tibial nerve in the tarsal tunnel, 2) the medial plantar nerve in the medial plantar tunnel, 3) the lateral plantar nerve in the lateral plantar tunnel, and 4) the calcaneal nerve in one or more calcaneal tunnels (● Fig. 4).

The tibial nerve in the tarsal tunnel is approached through an incision that is posterior to the medial malleolus, and midway to the Achilles tendon. It begins just proximal to the medial malleolus. An incision too close to the medial malleolus can cause a painful scar due to a neuroma of a posterior branch of the saphenous nerve [32]. The flexor retinaculum is opened and its edges cauterized to prevent them from re-attaching postoperatively. If there is a mass within the tarsal tunnel, from an anomalous muscle or a ganglion, which is quite rare, it is removed. There is no need to do anything to veins in this region. The tibial nerve must be separated from the artery and vein, and inspected. The epineurium is opened, and a clear division of the medial and lateral plantar nerves within the tarsal must be observed. If there is intraneural fibrosis, an intraneural neurolysis is necessary. In about 5% of patients, there will be a high division of the tibial nerve into the medial and the lateral plantar nerves [19]. The tarsal tunnel is usually not the site of the chronic compression. This exposure permits the rest of the decompressions to proceed safely, and permits decompression of intraneural pressure within the tibial nerve if it exists. The tarsal tunnel ends when the flexor retinaculum divides to encompass the abductor hallucis brevis muscle (AHB).

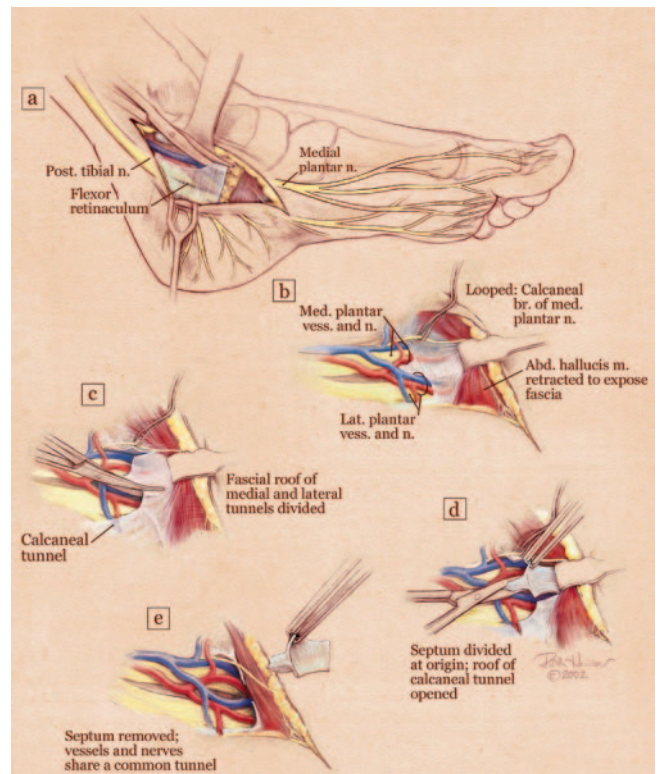


Fig. 4 Illustration of the four medial ankle tunnels. **a** Overview with flexor retinaculum open to show the tarsal tunnel. Note this tunnel ends at the abductor hallucis brevis (AHB). **b** The AHB has been retracted. Note the small nerve from the medial plantar nerve crossing the vessels to enter into the skin of the medial arch. This nerve must be protected. **c** The roof of the medial and of the lateral plantar tunnels has been divided. **d** The septum between the two tunnels is being divided. **e** The septum has been removed and the medial calcaneal tunnel has been decompressed. (With permission from dellon.com.)

To approach the medial and lateral plantar nerves, an incision is made towards the plantar aspect of the foot at the site of the lateral plantar tunnel. This incision is brought proximally to join the incision for the tarsal tunnel release. The superficial fascia of the AHB muscle is incised and gently spread. Care must be taken not to injure the small (< 1 mm) nerve that goes from the medial plantar nerve superficial to the vessels, enters into this fascia and emerges to innervate the medial ankle skin at about the site where the typical incision is made for a plantar fascia release. Injury to this small nerve will create a painful distal tarsal tunnel incision [31]. The ABH muscle is then swept off the underlying transverse ligament from which it is arising. The medial and lateral plantar tunnels are each cannulated with a straight clamp, demonstrating their tightness as the site of compression, and providing the pathway to divide the roof of each of these tunnels. The two tunnels are separated by a septum of varying thickness and length. It must be cauterized longitudinally, and then excised along with the roof of each of the two tunnels. The index finger is then placed into this space pushing distally. Additional fibrous bands are divided until the index finger enters the plantar aspect of the foot (● Fig. 5).

The medial calcaneal tunnel(s) are identified in one of two ways. First, there can be calcaneal nerves arising from the tibial nerve within the tarsal tunnel. These are identified in the posterior fat below the tibial nerve, and are followed distally to where they enter their tunnel. Second, from the fibrous roof of the lateral

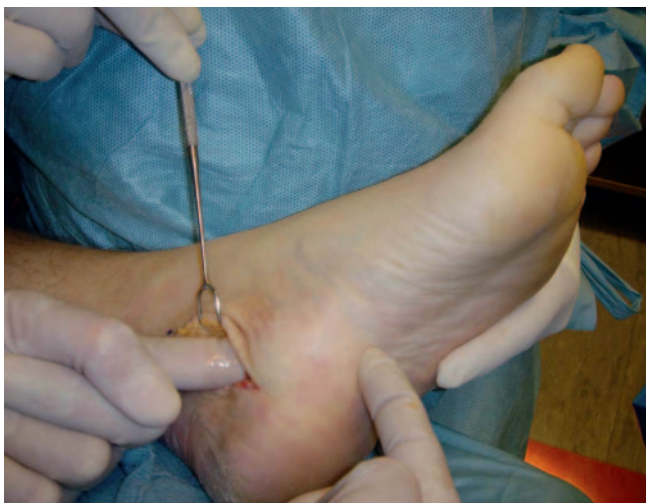

Fig. 5 Demonstration that after decompression of the four medial ankle tunnels, the surgeon's index finger can be passed from the incision into the plantar aspect of the foot.

plantar tunnel, that fascia is traced proximally and will be found to form the roof of the calcaneal branches that arise from the lateral plantar nerve before it enters its own lateral plantar tunnel. Each of these tunnels is gently spread and then the roof carefully divided so as not to injure one of the small branches of the calcaneal nerve. None of these branches are the one described by Baxter, which is a branch arising just before the motor innervation, and goes to the periosteum of the medial calcaneal tubercle. Marcaine, 0.5%, is infiltrated into the skin edges. The skin is closed with multiple 4–0 monocril intradermal sutures. Finally the skin is closed with interrupted and continuous 5–0 nylon sutures. The dressing is xeroform, sterile 4 × 4 gauze, then a kling or kerlex gauze wrap, and finally a bulky cotton, Robert Jones-type supportive dressing. This is also held on with kling, paper tape, and finally an ace wrap. The tourniquet is then let down. The ace wrap is removed after half an hour and is used just during the reflex period of vasodilation that exists after using the tourniquet (● Fig. 6).

Post-Op Management

Post-operatively, the patient will be allowed full weight bearing immediately and will use a walker for three weeks. The goal of walking is to minimize ankle range of motion so that the sutures do not pull out, yet still permit nerve gliding. The dressing is removed after the 7th day, and the patient is allowed to get the sutures wet, but must apply betadine twice a day to the incisions. The patient changes chairs each hour while awake to permit nerve gliding and minimize the risk of a deep vein thrombosis. The sutures at the knee are removed at the 14th day and at the foot/ankle level at the 21st day. Following removal of the sutures at the ankle, the patient is begun on water walking in a heated pool as a form of therapy. This should occur at least twice a week, and preferably three times a week. No other therapy is usually necessary. The patient will then progress through increasing degrees of ambulation and activity as tolerated. As pain diminishes, pain medication is decreased. In the patient who did not have pre-op pain, and who experiences pain due to

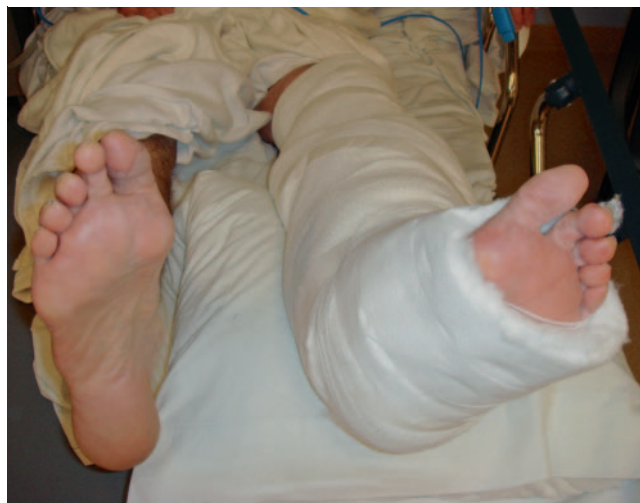

Fig. 6 Typical post-operative bulky supportive dressing.

nerve regeneration, a regimen of neuropathic pain medication can be started and the opioids continued as needed. Repeat neurosensory testing is done at 6 to 12 weeks postoperatively to document sensory recovery. It may be done sooner if the patient is experiencing significant pain, as the neurosensory test will document a nerve regeneration pattern that is reassuring to the patient and to the physician as well. The contralateral side may be operated on as early as 6 weeks later, if there has been sufficient documentation of pain relief or sensory recovery. Typically, most patients wait about three months to have surgery on the contralateral side. The longest time interval has been one year.

Tips for Avoiding Complications

The most common “complication” is that between 10 and 20% of patients will not improve following this surgery. The most common cause for this is previous back surgery with residual symptoms in the legs from the back problem. This is extremely difficult to identify pre-operatively in the presence of a neuropathy and in the presence of peripheral nerve compressions. A second cause of failure to improve is another site of nerve compression. Just recently we have focused upon entrapment of the tibial nerve proximally, at the calf level, where the tibial nerve goes beneath the soleus arch. There will be tenderness at the location and weakness in toe flexion. This site can be decompressed through a medial calf incision, going deep to the medial gastrocnemius muscle, and dividing this arch. The second most common complication is wound-healing problems. The most common site is the medial ankle incision. In about 5% of patients this may become red or may open. The sutures will create a problem with the skin with early ambulation, but such ambulation is critical to prevent the tibial nerve from becoming scarred in the surgical site. The patient is given i.v. antibiotics prior to inflating the tourniquet and for one week postoperatively. With advanced neuropathy, there is no pain at this incision site to warn the patient that the ankle is moving too much. Use of the bulky supportive bandage for the first week and the walker for three weeks, with the patient initiating each step by lifting the knee first will minimize suture/skin trauma. In

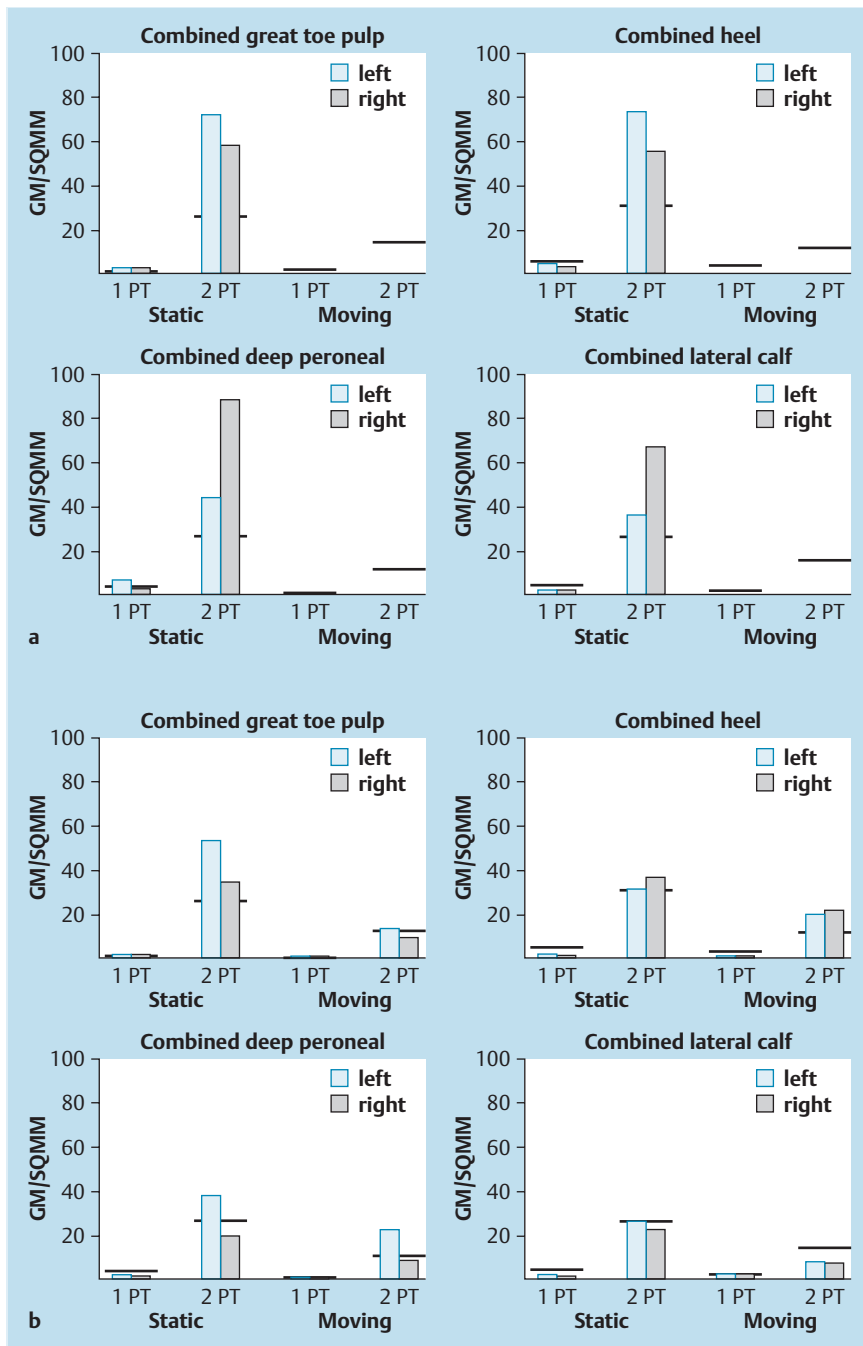


Fig. 7 a and b Neurosensory testing with the Pressure-Specified Sensory Device™. **a** Pre-operative testing documents a bilateral sensory neuropathy with axonal loss. The grey bar represents the right foot and the blue bar the left foot. The y axis represents pressure applied for the patient to be able to distinguish the stimulus. The black horizontal lines are the 99% confidence limits for age-matched normal data. The grey and blue bars are symmetrically elevated for both the peroneal and the tibial nerves, consistent with a neuropathy. The asterisk means that two-point discrimination distance is abnormal, consistent with axonal loss. **b** Post-operative testing demonstrates regeneration of sensory axons, now to almost normal levels.

my personal experience, no wound has had to be skin grafted. Six patients over 20 years have required secondary healing. Also, be careful not to cauterize the dermis while obtaining hemostasis. Pre-op attention to blood flow is critical to wound healing. To date, none of my patients with neuropathy have required secondary vascular surgery intervention. If a patient has had a previous bypass arterial graft, our current recommendation is **not** to use a tourniquet during the surgery [22].

An occasional patient has developed a deep vein thrombosis. We seek to prevent this by using compression stockings in the operating room on the contralateral leg, and having the patient ambulate immediately and often, albeit for short distances, during the early postoperative period. If the patient is driving more than 1.5 hours home after surgery, they are told to stop the car each

hour and get out and then get back into the car through the opposite side of the car.

Patients must be informed that they may have a neurological downgrade in motor or sensory function, but they are usually quite impaired prior to surgery, and this downgrading is extremely rare, happening less than 0.5% of the time. Prevention requires attention to the above surgical details and meticulous, gentle, peripheral nerve surgical skills.

Example of Surgery

▼ A 66-year-old man had a five-year history of numbness progressing to burning pain in both of his feet. The symptoms involved each foot to about the same degree. He did not have lumbar

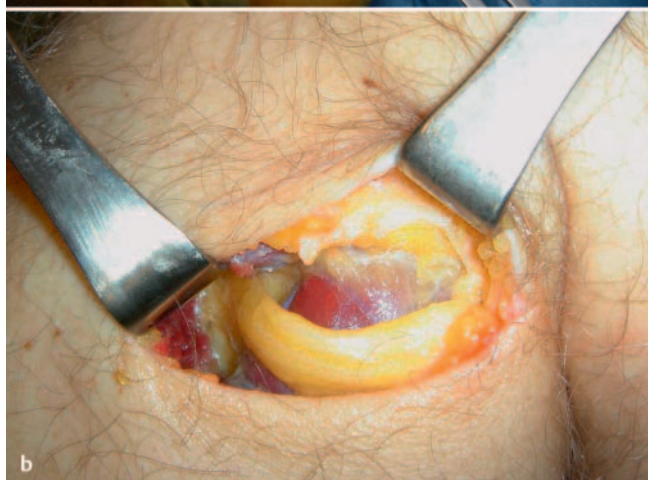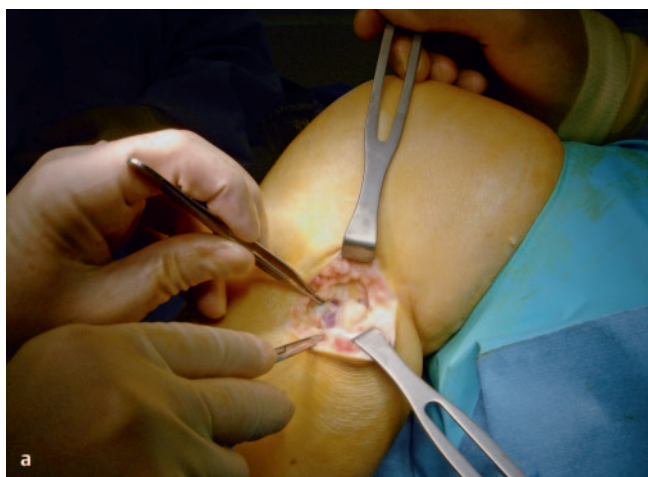


Fig. 8a and b Example of surgery on the left common peroneal nerve entrapment site. **a** Note the yellowish color of the common peroneal nerve as it approached the peroneus longus muscle. **b** Common peroneal nerve after neurolysis. Note indentation of the nerve.

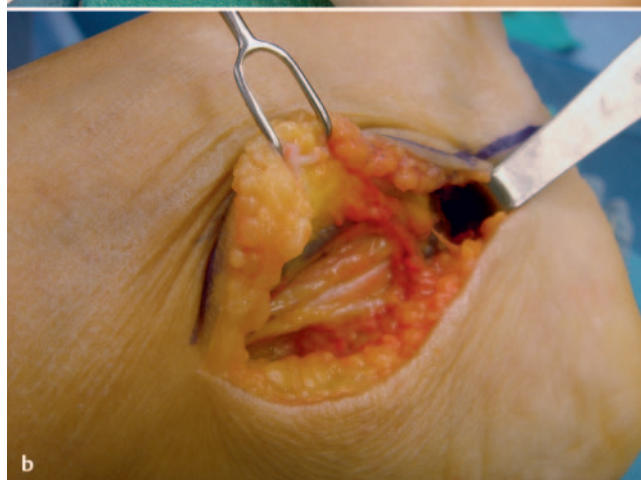
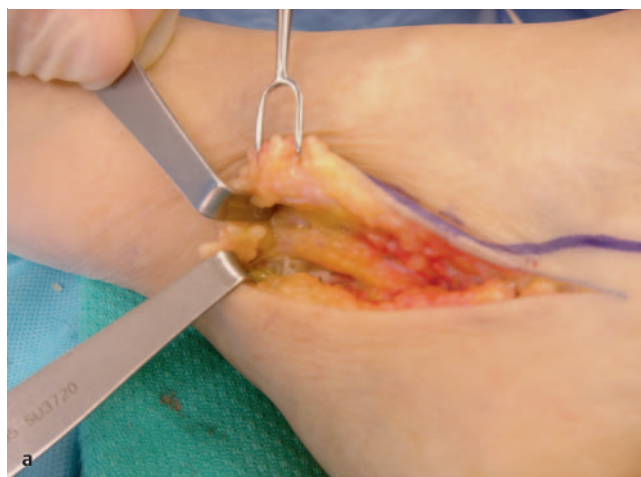
Fig. 9a and b Example of surgery on the left tarsal tunnel. **a** Note the yellowish change in color in the tibial nerve in the tarsal tunnel. **b** Within the tarsal tunnel, the tibial nerve has divided into medial and lateral plantar and calcaneal nerve. The retractor elevates the abductor hallucis, demonstrating the white roof of the medial and lateral tunnels that remains to still be divided.

spine problems. He was told he had a neuropathy of unknown etiology. The neuropathy was confirmed by electrodiagnostic studies. He was placed on gabapentin to help manage his level 8 out of 10 pain. He was overweight and had a family history of diabetes. His cholesterol and blood pressure were both elevated and he was on appropriate medications for each of these conditions. Three years ago he was given the diagnosis of non-insulin requiring diabetes mellitus, and his foot symptoms were said to be due to diabetic neuropathy. He was taking an oral medication for his diabetes and his last HbA1c was 6.8. He had begun to lose his balance and had fallen twice without having sustained a fracture. He did not have a history of ulceration in his foot. His podiatric physician had prescribed special shoes to prevent his developing an ulceration. His podiatric physician had read in the July 2007 issue of *Clinics in Podiatric Medicine and Surgery* an article describing hope for patients like this one if there were a superimposed nerve compression [50], and that doctor had referred him to seek consultation about the possibility of having a nerve decompression.

At the time he was first examined, he was found to have a positive Hoffmann-Tinel sign bilaterally present over the common peroneal nerve at the fibular neck, the deep peroneal nerve over the dorsum of the foot and the tibial nerve in the tarsal tunnel,

demonstrating that he did have localized sites of chronic nerve compression present in each lower extremity. He did not have a Hoffmann-Tinel sign over the superficial peroneal nerves, nor was the tibial nerve tender behind the calf. He had mild wasting of his abductor hallucis, but he did not have clawing of his toes. He had weakness in his extensor hallucis longus muscle. He had normal strength in his toe flexors. There was a strong posterior tibialis pulse present bilaterally and no pedal edema. His initial neurosensory test with the Pressure-Specified Sensory Device™ documented a sensory neuropathy with axonal loss (● Fig. 7a).

He was determined to be an excellent candidate for peripheral nerve decompression, and was scheduled to have a neurolysis of the common peroneal nerve at the fibular neck, neurolysis of the deep peroneal nerve over the dorsum of the foot, and a decompression of the four medial ankle tunnels (since three incisions are made, this has been termed the “Dellon Triple”).

At surgery, on the left foot, the common peroneal nerve was found to be infiltrated by fat, and to be severely compressed (● Fig. 8a and b).

The tibial nerve in the tarsal tunnel also demonstrated signs of fatty infiltration, and tightness in the medial and lateral plantar tunnels (● Fig. 9a and b).

Immediately after surgery, in the recovery room, when his left plantar skin was gently stroked, it felt ticklish and he laughed (a “positive” “test Tickle” sign). After surgery, his pain level in the left foot fell to 4 out of 10, and by the 3rd post-operative month, his repeat neurosensory testing demonstrated nerve regeneration in his left foot.

At 4 months after the first surgery, he had the same surgery on his right foot. By 7 months after the first surgery, with neurosensory testing documenting recovery to almost normal levels of sensibility in both of his feet (● Fig. 7b), he had regained his balance and had no further falls. With recovery of sensibility, his likelihood of ever developing an ulceration or having an amputation (other than for vascular reasons) was greatly reduced. He was asked to return in one year for follow-up.

Conflict of Interest: I own Sensory Management Services, LLC, which produces the Pressure-Specified Sensory Device.



A. Lee Dellon

Born April 18, 1944 in Bronx, New York, USA. A. Lee Dellon graduated from Johns Hopkins University in 1966 and from the Johns Hopkins School of Medicine in 1970. He then completed eight years of additional training, including two years of surgery training at Columbia-Presbyterian Hospital in New York City, and two years of research at the

National Cancer Institute, Surgery Branch, of the National Institutes of Health. He completed a Plastic Surgery Residency at the Johns Hopkins Hospital and a Hand Surgery Fellowship at the Raymond M. Curtis Hand Center, both in Baltimore. Dr. Dellon has received the Certificate of Added Qualifications in Hand Surgery and is Board Certified in Plastic Surgery. He is currently a Professor of Plastic Surgery and a Professor of Neurosurgery at the Johns Hopkins University School of Medicine. He received his PhD from University of Utrecht, Netherlands, for his work in preventing ulceration and amputation in patients with nerve compression and diabetic neuropathy. Doctor Dellon’s research interests center on neural regeneration. In the basic research laboratory, his work included models for peripheral nerve compression, neuroma treatment, neural regeneration through absorbable conduits, and diabetic neuropathy. Dr. Dellon’s clinical work is focused on computer-linked devices to measure sensibility, treatment strategies for pain due to neuroma, use of bioabsorbable tubes as a substitute for nerve grafts, treatment of facial pain and of groin pain, and treatment of the symptoms of peripheral neuropathy related to nerve compression, whether due to diabetes, chemotherapy, or unknown causes. He has won 23 national research awards and is the author of seven books, 78 book chapters, and more than 400 articles published in peer-reviewed journals. Doctor Dellon is a founding member and past president of the American Society for Peripheral Nerve. He has been Vice President of the American Society of Reconstructive Microsurgery. He is the Director of the Dellon Institutes for Peripheral Nerve Surgery®. His most recent book is PAIN SOLUTIONS, a book of hope for people in pain, available on his website, www.dellon.com.

References

- 1 AAEM Quality Assurance Committee. Literature review of the usefulness of nerve conduction studies and electromyography for the evaluation of patients with carpal tunnel syndrome. *Muscle Nerve* 1993; 16: 1392–1414
- 2 American Diabetes Association. Economic costs of diabetes in the U.S. in 2002. *Diab Care* 2003; 26: 917–932
- 3 Argoff C, Backonja M, Belgrade MJ et al. Consensus guidelines: treatment planning and options. *Mayo Clinic Proc* 2006; 81 (Suppl.4): S12–S25
- 4 Aszmann OA, Kress KM, Dellon AL. Results of decompression of peripheral nerves in diabetics: a prospective, blinded study. *Plast Reconstr Surg* 2000; 106: 816–822
- 5 Aszmann OC, Tassler PL, Dellon AL. Changing the natural history of diabetic neuropathy: incidence of ulcer/amputation in the contralateral limb of patients with a unilateral nerve decompression procedure. *Ann Plast Surg* 2004; 53: 517–522
- 6 Bae S, Biddinger K, Shon L. Independent, retrospective review of surgical nerve decompression for diabetic neuropathy. Presented at the Amer Acad Orthop Surg Foot & Ankle Soc meeting, San Diego, February 2007
- 7 Biddinger KR, Amend KJ. The role of surgical decompression for diabetic neuropathy. *Foot Ankle Clin* 2004; 9: 239–254
- 8 Boulton AJM, Arezzo JC, Malik RA et al. Diabetic somatic neuropathies. *Diabetes Care* 2004; 27: 1458–1486
- 9 Chafee H. Decompression of peripheral nerves for diabetic neuropathy. *Plast Reconstr Surg* 2000; 106: 813–815
- 10 Chaudhry V, Stevens JC, Kincaid J et al. Practice advisory: utility of surgical decompression for treatment of diabetic neuropathy: report of the Therapeutics and Technology Assessment Subcommittee of the American Academy of Neurology. *Neurology* 2006; 66: 1805–1808
- 11 Cornblath DR, Vinik A, Feldman E et al. Commentary: surgical decompression for diabetic sensorimotor polyneuropathy. *Diab Care* 2007; 30: 421–422
- 12 Dellon AL. Optimism in diabetic neuropathy. *Ann Plast Surg* 1988; 20: 103–105
- 13 Dellon AL. Entrapment of the deep peroneal nerve on the dorsum of the foot. *Foot and Ankle* 1990; 11: 73–80
- 14 Dellon AL. Treatment of symptoms of diabetic neuropathy by peripheral nerve decompression. *Plast Reconstr Surg* 1992; 89: 689–697
- 15 Dellon AL. Decompression of peripheral nerves for symptoms of diabetic neuropathy: pain management considerations. *The Pain Clinic* 2001; 3: 11–16
- 16 Dellon AL. Prevention of foot ulceration and amputation by decompression of peripheral nerves in patients with diabetic neuropathy. *Ostomy Wound Manage* 2002; 48: 36–45
- 17 Dellon AL. Medical and surgical management of diabetic neuropathy. *Clinics in Podiatric Med and Surg* 2007; 24: 425–428
- 18 Dellon AL, Ebmer J, Swier P. Anatomic variations related to decompression of the common peroneal nerve at the fibular head. *Ann Plast Surg* 2002; 48: 30–34
- 19 Dellon AL, Kim J, Spaulding CM. Variations in the origin of the medial calcaneal nerve. *J Amer Pod Med Assoc* 2002; 92: 97–101
- 20 Dellon AL, Mackinnon SD. Tibial nerve branching in the tarsal tunnel. *Arch Neurol* 1984; 41: 645–646
- 21 DiNucci K. Results of decompression of multiple lower extremity peripheral nerves in diabetic with symptomatic neuropathy. Presented at the Amer College of Foot and Ankle Surgery meeting, New Orleans, March 2005
- 22 Ducic I, Chang SB, Dellon AL. The use of tourniquet in reconstructive surgery in patients with previous ipsilateral lower extremity revascularization: is it safe? A survey. *J Reconstr Microsurg* 2006; 22: 183–189
- 23 Ducic I, Taylor NS, Dellon AL. Relationship between peripheral nerve decompression, gain of pedal sensibility and balance in patients with peripheral neuropathy. *Annals of Plastic Surg* 2006; 56: 145–150
- 24 Dyck Jr JP, Dyck Sr JP, Klein CJ et al. Does impaired glucose metabolism cause polyneuropathy? Review of previous studies and design of a prospective controlled population-based study. *Muscle Nerve* 2007; 36: 536–541
- 25 Dyck PJ, Kratz KM, Karnes JL et al. The prevalence by staged severity of various types of diabetic neuropathy, retinopathy, and nephropathy in a population-based cohort: the Rochester Diabetic Neuropathy Study. *Neurology* 1991; 43: 817–824

- 26 Dyck PJ, Ziegler D, Norell JE et al. Challenges in design of multicenter trials: end points assessed longitudinally for change and monotonicity. *Diab Care* 2007; 30: 2619–2625
- 27 Feyler S, Rawstron A, Jackson G et al. Thalidomide maintenance following high-dose therapy in multiple myeloma: a UK myeloma forum phase 2 study. *Br J Haematol* 2007; 139: 429–433
- 28 Greenwald D, Moffitt M, Cooper B. Effective surgical treatment of cubital tunnel syndrome based upon provocative testing without electrodiagnostics. *Plast Reconstr Surg* 1999; 104: 215–218
- 29 Hossain P, Kowar B, Nahas ME. Obesity and diabetes in the developing world. A growing challenge. *New Eng J Med* 2007; 356: 213–215
- 30 Ivers RQ, Mitchell P, Cumming RG et al. Diabetes and risk of fracture. *Diabetes Care* 2001; 24: 1198–1203
- 31 Kim J, Dellon AL. Neuromas of the calcaneal nerves: diagnosis and treatment. *Foot Ankle Internat* 2001; 22: 890–894
- 32 Kim J, Dellon AL. Tarsal tunnel incisional pain due to neuroma of the posterior branch of saphenous nerve. *J Amer Pod Med Assn* 2001; 91: 109–113
- 33 Latov N. Diagnosis of CIDP. *Neurology* 2002; 59 (12 Suppl. 6): S2–S6
- 34 Lee C, Dellon AL. Prognostic ability of Tinel sign in determining outcome for decompression surgery decompression surgery in diabetic and non-diabetic neuropathy. *Ann Plast Surg* 2004; 53: 523–527
- 35 Mackinnon SE, Dellon AL. Homologies between the tarsal and carpal tunnels: Implications for treatment of the tarsal tunnel syndrome. *Contemp Orthop* 1987; 14: 75–79
- 36 Maloney CT, Valdivia JV, Weinand M. Nerve decompression results in a consecutive series of 165 patients with neuropathy. Presented at the Assoc Neurologic Surgeons, Phoenix, Arizona, 2006
- 37 Massa E. Diabetic neuropathy: decompression of compressed lower extremity nerves. Presented at Internat Diab Fed meeting, Cape Town, S. Africa, Jan. 2007
- 38 Mont MA, Dellon AL, Chen F et al. Operative treatment of peroneal nerve palsy. *J Bone Joint Surg [Am]* 1996; 78: 863–869
- 39 Nelson SC, Little Jr ER. The 36 item Short-Form Health Survey for outcome evaluation for multiple lower extremity nerve decompressions in diabetic peripheral neuropathy: a pilot study. *J Amer Pod Med Assoc* 2007; 97: 121–125
- 40 Peek ME, Cargill MA, Huang ES. Diabetes health disparities: a systematic review of health care interventions. *Med Care Res Rev* 2007; 64 (Suppl. 5): 1015–1565
- 41 Perkins BA, Olaleye D, Bril V. Carpal tunnel syndrome in patients with diabetic polyneuropathy. *Diabetes Care* 2002; 25: 565–569
- 42 Piatt GA, Zgibor JC. Novel approaches to diabetes care; a population perspective. *Curr Opin Endocrin Diab Obes* 2007; 14: 158–165
- 43 Periera BM. Decompressive peripheral nerve surgery for the relief of neuropathic symptoms in diabetics. Presented at the Amer Assoc of Neurologic Surgeons, 2007
- 44 Rader AJ. Surgical decompression in lower-extremity diabetic peripheral neuropathy. *J Am Podiatr Med Assoc* 2005; 95: 446–450
- 45 Rather HM, Boulton AJM. Recent advances in the diagnosis and management of diabetic neuropathy. *J Bone Joint Surg [Br]* 2005; 87: 1605–1610
- 46 Rempel D, Evanoff B, Amadio PC et al. Consensus criteria for the classification of carpal tunnel syndrome in epidemiologic studies. *Am J Public Health* 1998; 88: 1447–1451
- 47 Rosson GD, Dellon AL. Superficial peroneal nerve anatomic variability changes surgical technique. *Clinical Orthop Rel Res* 2005; 438: 248–252
- 48 Schwartz AV, Sellmeyer DE, Ensrud KE et al. Older women with diabetes have an increased risk of fracture: a prospective study. *J Clin Endocrinol Met* 2001; 86: 32–38
- 49 Shafiroff B. Decompression of lower extremity nerves in neuropathy. Presented at Lower Extr Peripheral Nerve Surg meeting, Santa Fe, New Mexico, Oct. 2006
- 50 Siemionow M, Alghoul M, Molski M et al. Clinical outcome of nerve decompression in diabetic and non-diabetic peripheral neuropathy. *Ann Plast Surg* 2006; 57: 385–390
- 51 Siemionow M, Demir Y. Diabetic neuropathy, pathogenesis and treatment: a review. *J Reconstr Microsurg* 2004; 20: 241–252
- 52 Sorbe B, Andersson H, Boman K et al. Treatment of primary advanced and recurrent endometrial carcinoma with a combination of carboplatin and paclitaxel-long-term follow-up. *Int J Gynecol Cancer* 2008; 18: 803–808; epub 2007 Oct 18
- 53 Steck J. Results of decompression of lower extremity peripheral nerve for treatment of symptomatic neuropathy. Presented at Amer Soc Peripheral Nerve meeting, Puerto Rico, January 2005
- 54 Szabo RM, Slater RR, Farver TB et al. The value of diagnostic testing in carpal tunnel syndrome. *J Hand Surg [Am]* 1999; 24: 704–714
- 55 Tambwekar SR. Extended neurolysis of the posterior tibial nerve to improve sensation in diabetic neuropathic feet. *Plast Reconstr Surg* 2001; 108: 1452–1453
- 56 Valdivia JM et al. Surgical treatment of peripheral neuropathy: outcomes from 100 consecutive decompressions. *J Am Podiatr Med Assoc* 2005; 95: 451–454
- 57 Vinik AI, Mehrabyan A, Colen L et al. Focal entrapment neuropathies in diabetes. *Diabetes Care* 2004; 27: 1783–1788
- 58 Wieman TJ, Patel VG. Treatment of hyperesthetic neuropathic pain in diabetics; decompression of the tarsal tunnel. *Ann Surg* 1995; 221: 660–665
- 59 Williams E, Dellon AL. Intra-septal superficial peroneal nerve. *Microsurgery* 2007; 27: 477–480
- 60 Wood WA, Wood MA. Decompression of peripheral nerves for diabetic neuropathy in the lower extremity. *J Foot Ankle Surg* 2003; 42: 268–275
- 61 Yao Y, Wang R-Z. Peripheral nerve decompression (Dellon procedure) and diabetic neuropathy. *Chinese J Med* 2005; 10: 1756–1758
- 62 Yuksel F, Karagoz H, Yuksel F et al. Early and late results of nerve decompression procedures in diabetic neuropathy: a series from Turkiye. *J Reconstr Microsurg* 2008; 24: 95–101